



# A decade of the socket-shield technique: a step-by-step partial extraction therapy protocol

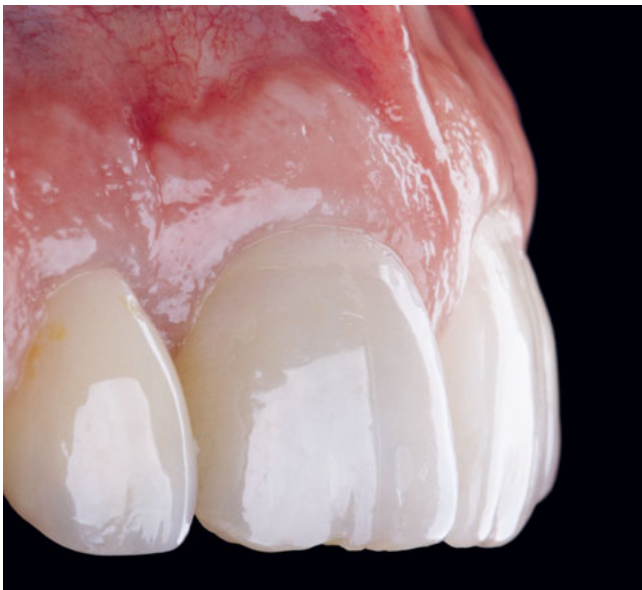**Howard Gluckman**, BDS, MChD, PhD  
Implant & Aesthetic Academy, Cape Town, South Africa

**Jonathan Du Toit**, BChD, Dip Oral Surg, Dipl Implantol, MSc  
Department of Periodontics and Oral Medicine, University of Pretoria, South Africa

**Maurice Salama**, DMD  
Department of Periodontics, University of Pennsylvania, Philadelphia, USA  
Department of Periodontics, Augusta University, Augusta, Georgia, USA

**Katalin Nagy**, DDS, DSc, PhD  
Professor, Faculty of Dentistry, Department of Oral Surgery University of Szeged, Hungary

**Michel Dard**, DDS, MS, PhD  
Professor, Department of Periodontics, Columbia College of Dental Medicine, Columbia, USA



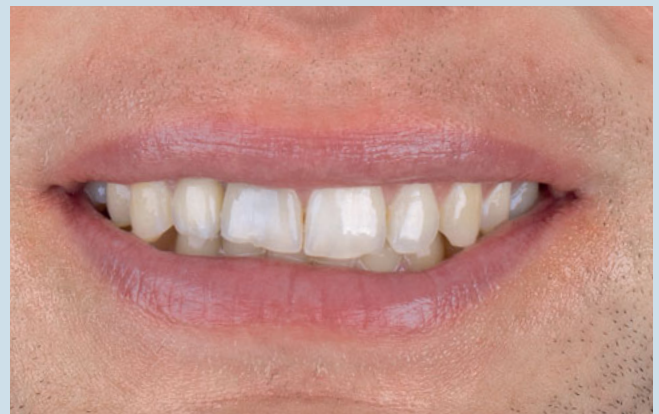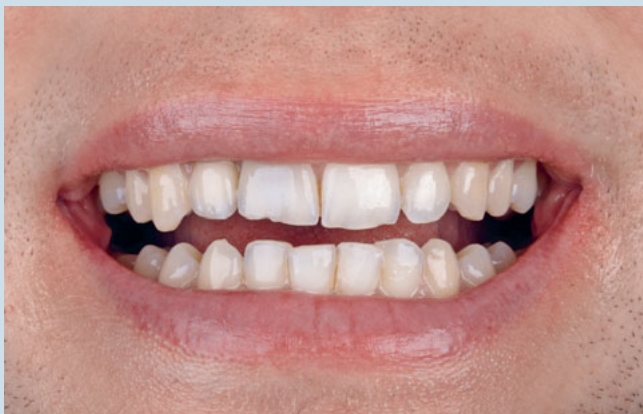Correspondence to: [Dr Howard Gluckman](#)  
Implant & Aesthetic Academy, 39 Kloof Street, Cape Town, South Africa, 8001; Telephone: +27 21 426 2300;  
Email: [docg@mweb.co.za](mailto:docg@mweb.co.za)

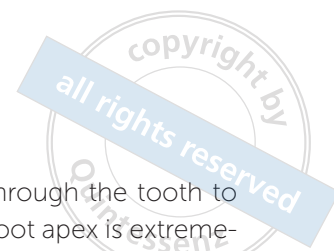## Abstract

Ten years have passed since Hürzeler and coworkers first introduced the socket-shield technique. Much has developed and evolved with regard to partial extraction therapy, a collective concept of utilizing the patient's own tooth root to preserve the periodontium and peri-implant tissue. The specifications, steps, instrumentation, and procedures discussed in this article are the result of extensive experience in refining the

socket-shield technique as we know it today. A repeatable, predictable protocol is requisite to providing tooth replacement in esthetic dentistry. Moreover, a standardized protocol provides a better framework for clinicians to report data relating to the technique with procedural consistency. This article aims to illustrate a reproducible, step-by-step protocol for the socket-shield technique at immediate implant placement and provisionalization for single-rooted teeth.

*(Int J Esthet Dent 2020;15:212–225)*





## Introduction

Systematic reviews have long since highlighted the long-term esthetic and biological challenges of placing implants into postextraction sockets.<sup>1</sup> Hürzeler and co-workers<sup>2</sup> met those challenges with the first introduction of the socket-shield technique. The first studies by the original working group did not describe in detail the exact steps and instrumentation required, and yet much has subsequently been published on the technique.<sup>2-4</sup> Those first studies prescribed the following parameters: the implant osteotomy was prepared through the tooth that created a socket-shield; the socket-shield was prepared 1 mm above the crestal bone and was approximately one third of the root length; the implant was placed against the socket-shield in two out of four cases; and an enamel matrix derivative may or may not have been required.

A modification of the technique was published by Gluckman et al.<sup>5,6</sup> Later, the same working group published 4-year data of the modified technique in the largest patient cohort to date.<sup>7</sup> Those results showed that complications can occur; however, the complication data need to be correctly interpreted. The socket-shield failed and was removed in only three out of 128 cases. This was due to overpreparing socket-shields until they were too thin, resulting in weaker socket-shields that were prone to mobility. The remaining complications were all immediately manageable and had no impact on the long-term success of the socket-shields or the implants.

Ten years after the introduction of the socket-shield technique, the data now demonstrate that there are challenges with the original technique and its similar variation by other authors.<sup>8</sup> First, supracrestal socket-shields and a lack of prosthetic space may increase the risk of exposure. Second,

drilling an osteotomy through the tooth to reach and remove the root apex is extremely challenging. The majority of maxillary anterior teeth are retroclined and do not coincide with either an implant osteotomy or prosthetic screw retention.<sup>9</sup> There is a major drawback with both described techniques; the one utilizing implant drills to drill through the root, and the other utilizing root resection burs to section the tooth. The drawback is that the accuracy of reaching the apex and not veering off course or drilling past the apex poses a significant technical challenge.

Thus, for a technique to be widely accepted, its procedures and outcomes need to be reproducible and predictable for the majority who utilize it. This article therefore describes a step-by-step partial extraction therapy protocol to improve reproducibility and limit known complications.

## Step-by-step protocol

As with all treatment approaches, it is mandatory to assess the patient and site in order to select an appropriate treatment option. Criteria for selecting the socket-shield technique may not have been clearly prescribed in the literature to date. The following paragraphs thus describe the criteria to be met for the partial extraction therapy protocol.

## Indications

Indications for partial extraction therapy have been previously mentioned in the literature, albeit in brief.<sup>6</sup> The primary indication for immediate implant placement would be the removal of a tooth or root and the placement of an implant within the same day (type 1 placement).<sup>10</sup> The indications for extraction could be numerous. However, to retain a facial root portion as a socket-shield, there are more implicit prerequisites (Ta-



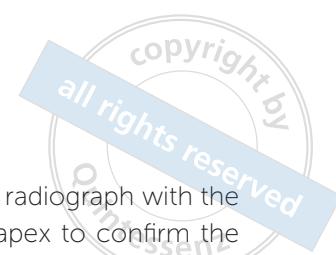ble 1). Possible scenarios could include a tooth that lacks a ferrule, rendering it unrestorable without adjunctive crown lengthening surgery. In the anterior esthetic zone, crown lengthening of a single tooth without also treating the adjacent teeth creates asymmetry and is typically contraindicated. Orthodontic extrusion with fiberotomy or followed by crown lengthening surgery is a possible alternative, although the previous failure of endodontic treatment, the failure of extensive restorative treatment, and extensive caries are typically indicators of a low prognosis for repeated treatment. Should the patient and clinician decide against such a treatment, the socket-shield technique may be an option.

**Contraindications**

The root should not have a vertical fracture that involves the facial portion intended to be retained. Neither should horizontal fracture be located at a point so far apical that it compromises the facial bone crest. Apical endodontic pathology is not an absolute contraindication. Infection and pathology that perforates the facial aspect of the root and is inaccessible to instrumentation for removing it is arguably not an ideal scenario. Clinical discretion is advised. Similarly, extensive apical pathology such that primary stability of the immediate implant is not achievable is, however, a contraindication. In such a case, an alternative partial extraction therapy such as the delayed sock-

**Table 1** Case selection criteria for the socket-shield technique at immediate implant placement at anterior/non-molar teeth

Indications	Contraindications	Relative contraindications
Unrestorable tooth	Deep subgingival horizontal root fracture	Deep residual periodontal bony defects
Extensive caries	Vertical fracture of facial root aspect	Extensive apical pathology
Lack of ferrule	Extensive facial bone dehiscence	Apicofacial bone fenestration
Cervical fracture	Mobile socket-shield	
Vertical/oblique root fracture	Ankylosed tooth, significantly apical to adjacent teeth	
Failed endodontic treatment(s)	Lack of experience/skill/training in immediate implant placement	
Failed restorative treatment(s)		
Tooth/root resorption		



et-shield technique described by Glocker et al<sup>11</sup> is advised. Bone in the area as well as the extent of any pathology must be evaluated by cone beam computed tomography (CBCT). The presence of bone facial to the root must be verified.

### *Decoronation and endodontic post management*

1. Measure the root length on the CBCT scan from the visible gingival margin to the root apex. (Technical note: The vestibule must be reflected during CBCT acquisition by retractor or cotton rolls to enable the visualization of the soft tissue).
2. Decoronate the tooth (if the crown is present) to the gingival level, gaining access to the root canal space (Fig 1a to d). Ensure that the adjacent tooth crowns, restorations, gingival margin, and papillae are not damaged by the bur.
3. If a post is present, it must be carefully removed. Shield preparation should be carried out with an irrigated high-speed handpiece coupled to a rapid-cutting diamond or root resection bur. The cut should not extend around the post fully, but rather be limited to the palatal portion to avoid damaging the facial root portion. The cut is progressed slowly and apically in a sweeping motion, on the palatal side until the post loosens and can be removed (or if securely bonded, be cut away). Thereafter, conventional socket-shield preparation steps can be followed.

If no post is present, progress to the following steps after measuring the root length on the CBCT.

### *Canal preparation and depth measurement*

1. Widen the tooth canal with a number 1 Gates Glidden bur (Fig 1b) right down to the apex of the root. This removes canal tissue or endodontic filling material, if

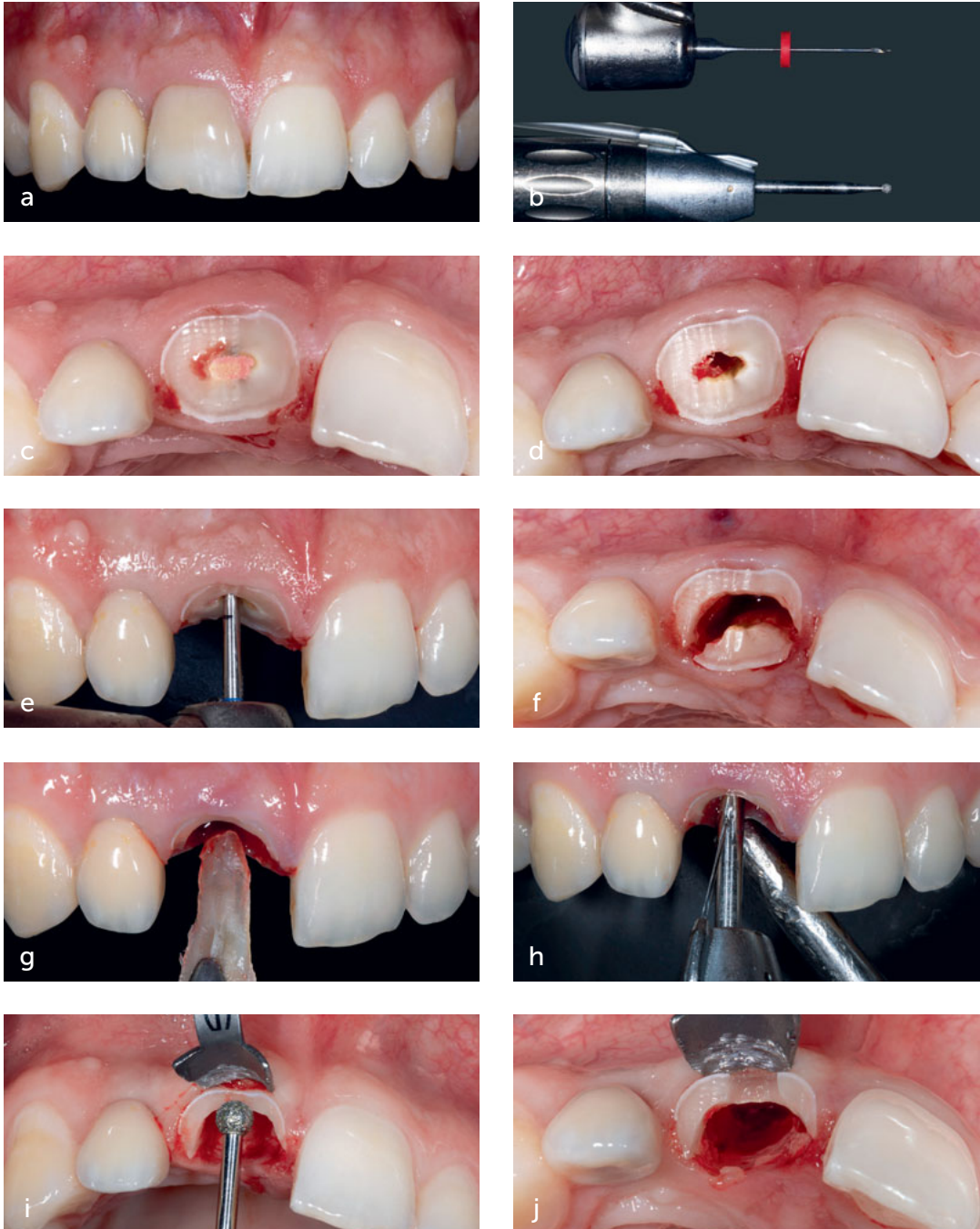
present. Then take a radiograph with the bur inserted to the apex to confirm the root length (Fig 3j). (An endodontic file and apex locator may be used instead.)

2. The canal is then widened further by successive increases in Gates Glidden bur sizes to the confirmed root length, also drilled to the apex.
3. Following canal widening with the Gates Glidden burs, a long-shank root-resection bur is rotated directly down the root canal to the apex (Fig 1e). (A lance bur with an adjustable depth stop may be ideal for this step.) This is the start of the apex removal and is one of the most important steps in the technique.
4. Confirm depth, angulation, and apex removal with repeated radiographs. This confirms that drilling within the canal has not deviated and is important to ensure that perforation or injury to adjacent roots and structures does not occur.

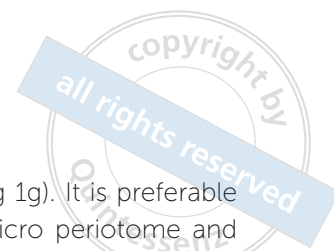### *Sectioning the root*

There is currently no consensus on the ideal socket-shield dimensions in terms of length, thickness, etc. The current authors previously reported that orthodontic displacement of smaller socket-shields is possible.<sup>7</sup> Experience has shown that a thinner socket-shield may be prone to flexure, fracture, and mobility, especially if the implant and its threads exert force against it.<sup>7</sup> It is also possible that there are no negative consequences of contact between implant and socket-shield.<sup>2</sup> Nonetheless, it is recommended that the facial root portion be thicker (roughly half the thickness from root canal to outer surface) so that it is more robust and resilient to any forces.<sup>6</sup> A larger, longer socket-shield also means greater attachment via its periodontal ligament to bundle bone and hence greater stability, preventing mobility. Bäumer et al<sup>4</sup> did not specify an exact length. The current authors understand from the published diagrams





**Fig 1** (a) Preoperative situation: maxillary right central incisor is untreatable, planned for extraction. Extraction of central incisor would be detrimental to adjacent lateral incisor implant that already had some marginal bone loss. (b) Contra-angled handpiece with Gates Glidden bur (top) and straight handpiece with long-shank round diamond bur (below). (c) Tooth decoronated, no endodontic post in place, canal obturated previously with endodontic filling material. (d) Endodontic filling material removed and depth confirmed with Gates Glidden burs. (e) Long-shank root-resection bur rotated to confirmed depth, to root apex, down widened canal. (f) Root sectioned mesiodistally, creating an arc. (g) Palatal root portion removed. (h) Long-shank diamond bur rotated in a straight handpiece at confirmed depth, to remove root apex and apical tissue; also upward along root to remove canal contents. (i) Soft tissue reflected with a gingival protector and socket shield reduced to bone crest. (j) Reduction started in midfacial aspect, then levelled laterally to bone crest.



that the socket-shield appears greater than a third and less than a half of the root length.<sup>4</sup> This length may be adequate. However, if the majority of maxillary anterior roots are Class II (retroclined), it would be unsafe to cut the root shorter to this length due to the risk of perforating the facial bone.<sup>9</sup> It is unclear how it was possible to create this length of socket-shield using the original protocol of drilling through the root with the implant osteotomy preparation drills without perforating the facial bone.

Apically, however, the bone is usually more abundant, hence it is suggested to section close to the apex while also removing it (described below). This is achieved by enlarging the canal all the way to the apex, as described above. In this manner, a longer socket-shield of approximately two thirds of the root length can be prepared. When preparing the socket-shield, it is proposed that the concept of 'as large as possible but reduced as much as necessary' is adhered to.

1. After enlarging the canal, section the root mesiodistally. Insert the root resection bur to the apex of the canal, then carefully cut the mesial and distal canal wall by making painting motions while exiting the canal with the bur. Repeat these motions successively, until a mesiodistal slot is created. Whilst sectioning the root vertically, create a curved arc rather than a straight line (Fig 1f). Also, roots are tapered, and thus the range of mesiodistal motion should decrease apically so as to section the root rather than drilling into the surrounding bone.
2. The socket-shield should extend from the mesial to the distal line angle. In cases where adjacent implants are expected, the shield can be extended into the interproximal space to ensure the maintenance of the interproximal bone.
3. Once sectioning the root is considered complete, remove the lingual root portion by delivering it into the space creat-

ed by sectioning (Fig 1g). It is preferable to do this with a micro periosteal and elevator. Ensure finger pressure on the facial portion of the root to prevent inadvertent pressure in a facial direction and to support the facial root portion at the bony plate. Movement at the facial aspect may indicate incomplete sectioning of the root.

#### *Apex removal*

1. Figure 1g shows how the root fractured at the apex after sectioning with the bur, with the majority of the root apex visible and attached to the lingual portion. If this had not occurred, it is likely that the apex would have remained within the socket, as part of the facial root portion. Once the lingual root portion is removed, the root apex (diseased or otherwise) and all endodontic filling materials must be carefully removed. This must be verified by a periapical radiograph. Radiopaque endodontic filling material, visible canal anatomy, and/or visible root apex on the radiograph require re-instrumentation with a bur for further removal. Typically, the bur is inserted into the socket apex without rotation. This carefully locates the apex without inadvertently drilling any areas other than the desired apical root and tissues. Once positioned at the apex, the bur is rotated at moderate speed (use clinical discretion). Slight and very careful widening of the apical area is performed. Careful vertical sweeping motions with the bur, starting from the apex and moving coronally, removes the canal contents at the inner and facial aspect of the root canal, as well as any part of the apex that may have remained. Selecting a straight a slower 1:1 handpiece with a 2-3mm round diamond bur works well with the long roots of the maxillary canines (Fig 1h); a contra-angle handpiece may be more appropriate for use in the mandible.



2. Micro-curettes used under high magnification with focused light are used to curette and clean the apical area. Repeated rinsing with sterile saline is advised to remove debris. All apical pathology and soft tissue must be removed. Optional yet not essential may be the use of a laser to remove stubborn tissue tags from the bone.

#### *Coronal root preparation*

1. This is one of the most difficult steps in preparing the socket-shield and can lead to complications if not done correctly. First, the socket-shield should be reduced to bone level. Hürzeler and co-workers, who conceptualized the first socket-shield technique, originally proposed preparing the root to "approximately 1 mm coronal to the buccal bone plate."<sup>2</sup> However, later data revealed that supracrestal preparation frequently results in the exposure of the socket-shield through the overlying soft tissue.<sup>7</sup> To prevent this, reduce the socket-shield to bone level with a diamond bur, while carefully reflecting the soft tissue with a gingival protector (Fig 1i and j). Erroneously cutting the soft tissue during this step will damage and further thin the tissue. This is to be avoided, as it may lead to external socket-shield exposure.
2. Thereafter, thin the most coronal 2 mm of the internal aspect of the socket-shield with a large round diamond bur (Fig 2a). This creates a chamfer that allows for additional prosthetic space and a soft tissue seal around the prosthetic component of the implant.<sup>12</sup>
3. The socket-shield can then be carefully smoothed and all sharp areas removed. This is done with a long-shank fine-grit bur and red-ring speed-increasing handpiece. Take care not to remove too much root tissue at this late stage, although, as stated, there is no consen-

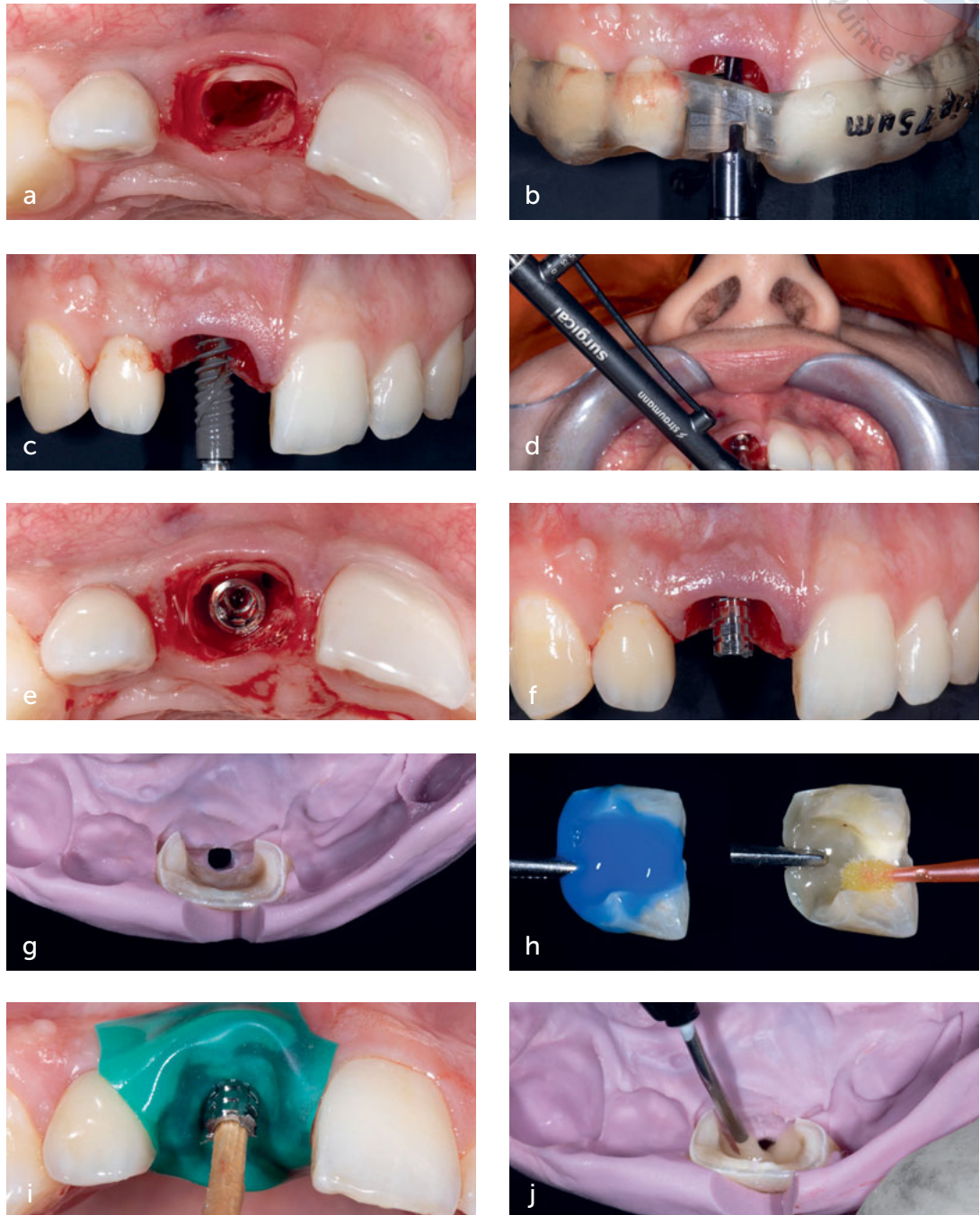
sus as to the ideal socket-shield thickness.

4. The final preparation step is to ensure that the socket-shield is firm and exhibits no mobility. Gently probe the inner dentin surface to confirm the absence of mobility, and take a periapical radiograph to ensure all the aforementioned steps are adhered to (Fig 4a).

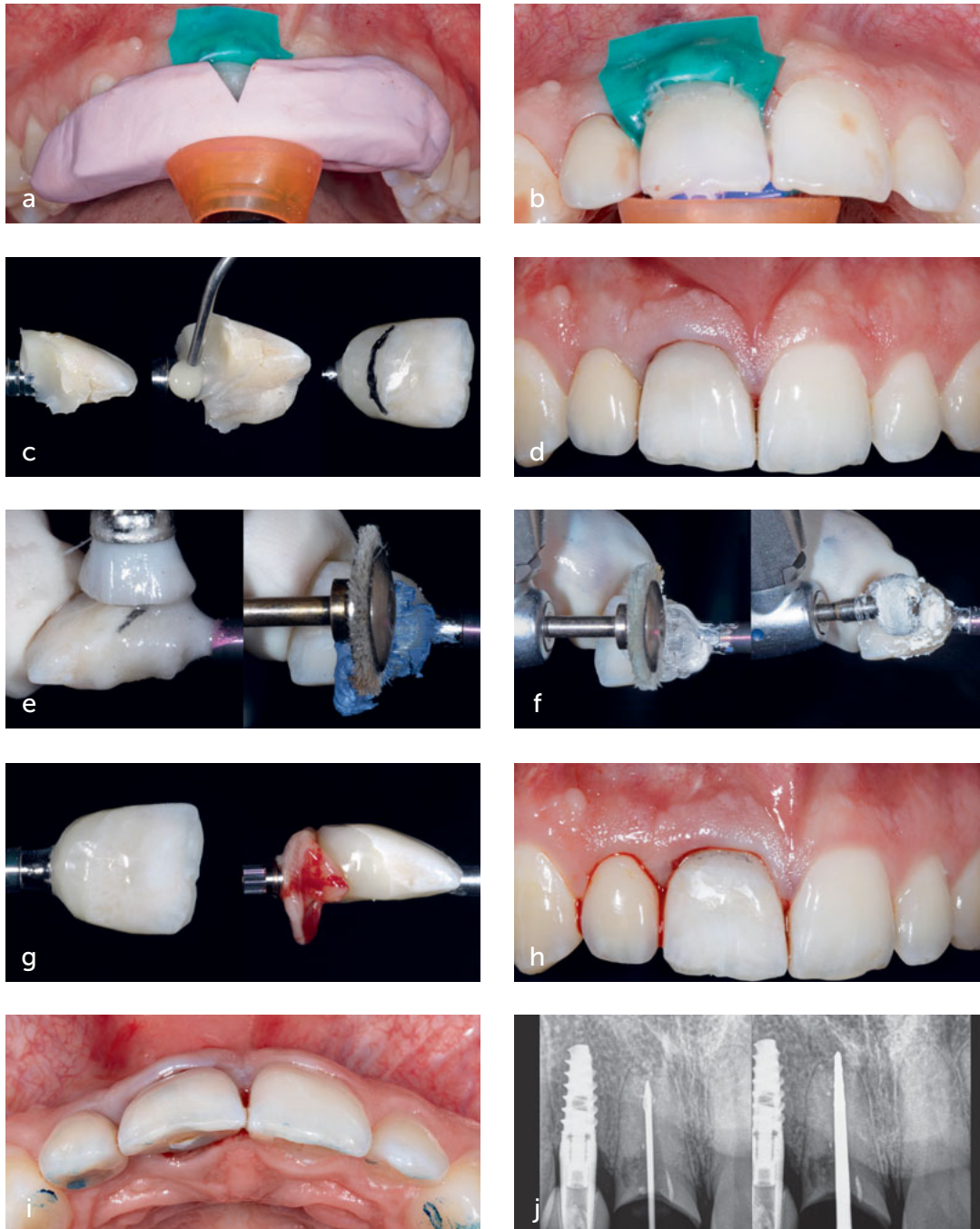

#### *Implant placement*

1. Next, the implant osteotomy is created lingual to the fully prepared socket-shield (Fig 2b to d). Correct three-dimensional restorative-planned placement is critical. However, some important factors require consideration. Where possible, ensure that the implant is placed further from the socket-shield toward the lingual, while always ensuring placement within the bony envelope (Fig 2e). This is contrary to the original protocol<sup>2</sup> of placing the implant against it. A greater buccal gap allows space for adequate coronal soft tissue thickness and a seal around the implant prosthetic component. Furthermore, placing the implant in contact with the socket-shield may unintentionally dislodge or even fracture it. To create the space facial to the implant to allow for bone growth between the socket-shield and the implant, as well as soft tissue healing at the coronal aspect, the implant should be as narrow as possible but as wide as necessary. This is determined by the tooth's anatomical site, choice of implant design, implant bulk material, and abutment connection type, as well as occlusal and prosthetic factors. Consider an implant that is suited to immediate placement, ie, an aggressive thread design, tapered implant body (platform switched), and preferably a purely tapered interference fit (misnamed 'cone Morse taper').

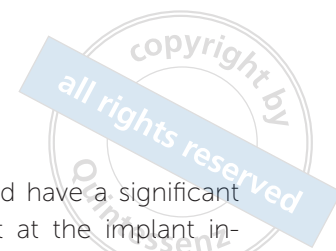



**Fig 2** (a) Fully prepared socket shield and internal beveled chamfer at bone crest. (b) Guided preparation of implant osteotomy lingual to socket shield. (c) Implant placement: Implant tapered with aggressive thread to better ensure primary stability at immediate placement. (d) Confirmation of insertion torque. (e) Implant positioned lingual to socket shield. (f) Provisional abutment cut to appropriate length and screw retained. (g) Patient's original tooth crown, prepared as a provisional crown, positioned in a polyvinylsiloxane template. (h) Etching of original tooth crown (left), then priming and bonding (right). (i) Rubber dam section to seal socket entrance with screw access blocked out. (j) Composite material flowed into prepared tooth crown within the template.



**Fig 3** (a) Composite material light cured through a hole in the template, bonding tooth crown to provisional abutment. (b) Template removed and additional light curing. (c) Subcritical contour developed by adding composite material, marking the gingival margin, and reducing the emergence profile into an S shape. (d) Provisional crown positioned in the mouth for confirmation. (e and f) Provisional crown thoroughly polished, sequentially by a silicone brush, rag wheel, pumice paste, and diamond paste. (g) Advanced platelet-rich fibrin (A-PRF) membrane placed at the subcritical contour of provisional crown. (h) Provisional crown screw-retained in final position. (i) Final occlusal adjustments. (j) Periapical radiographs corresponding corresponding to Figure 1e. Gates Glidden bur confirms root length (left); long-shank root-resection bur rotated to root length (right).



2. Placement depth is also critical. Placement should be 1.5 mm below the facial bone crest, and about 0.5 mm above the apical limit of the chamfer. Otherwise, limited bone may form between the socket-shield and the implant, and/or the socket-shield may be prone to pressure and orthodontic movement by the prosthetic component.

### *Management of the gap*

1. Currently, only one study has reported satisfactory clinical and radiographic outcomes after 1 year when the gap between the implant and socket-shield was not grafted with bone or a substitute material.<sup>13</sup> The grafting of this gap thus remains the clinician's prerogative until further data are reported. It is recommended, however, to graft this space, unless it is too small to accommodate the graft material. Bone or substitute material may prevent soft tissue ingrowth at the coronal aspect and help to stabilize the blood clot that is necessary for the organization into granulation tissue and then bone. Using a rapidly substituting calcium phosphosilicate putty may more accurately confirm bone infill on follow-up CBCT views.<sup>14</sup>

### *Management of the gingival seal*

1. The implant, socket-shield, and bone graft within the gap must be protected from the oral cavity. Thus, at immediate tooth replacement, a standard healing abutment by the manufacturer usually does not suffice. Constructing a customized healing abutment or an anatomical provisional crown is required (Figs 2f to j, 3a to i, 4b and c). It is also essential to support the original soft tissue profile as much as possible, in keeping with the principles of immediate implant placement.<sup>10</sup> The customized abutment should conform to the extraction socket

periphery and should have a significant undercut, narrowest at the implant interface, to allow for maximal soft tissue infill and to avoid exposure of the socket-shield. Similarly, the provisional crown should also have an undercut, more accurately an S-shaped emergence profile (Figs 3c and e).<sup>12</sup> The subcritical contour of the prosthetic components must also be highly polished. The necessary occlusal adjustments that limit function on the immediate implant and provisional restoration are also requisite and conclude the procedure.

2. After completion of healing, an individualized impression is then necessary to prevent pressure on the socket-shield and possible exposure. Thus, there should be no pressure or blanching of the soft tissue at final crown placement.

## Discussion

Immediate tooth replacement is likely to always be one of the most technically challenging procedures in dentistry, especially in the esthetic zone (Fig 4). The literature often states that immediate implant placement should be reserved for the skilled and highly trained clinician.<sup>1,10</sup> The current authors would agree. Moreover, carrying out the socket-shield technique requires detailed knowledge of the procedure and the possible pitfalls, anticipated complications, necessary instruments, and so forth.

If a socket-shield is an added challenge, then where does it fit into daily dental practice? The increase in the knowledge of the current authors resulted in some improvement to the socket-shield technique procedures, but much remains unknown such as the ideal size and dimensions of the socket-shield, the impact of the socket gap graft, the choice of bone material, and whether bone will form to the most coronal limit of the socket-shield toward the implant. Han



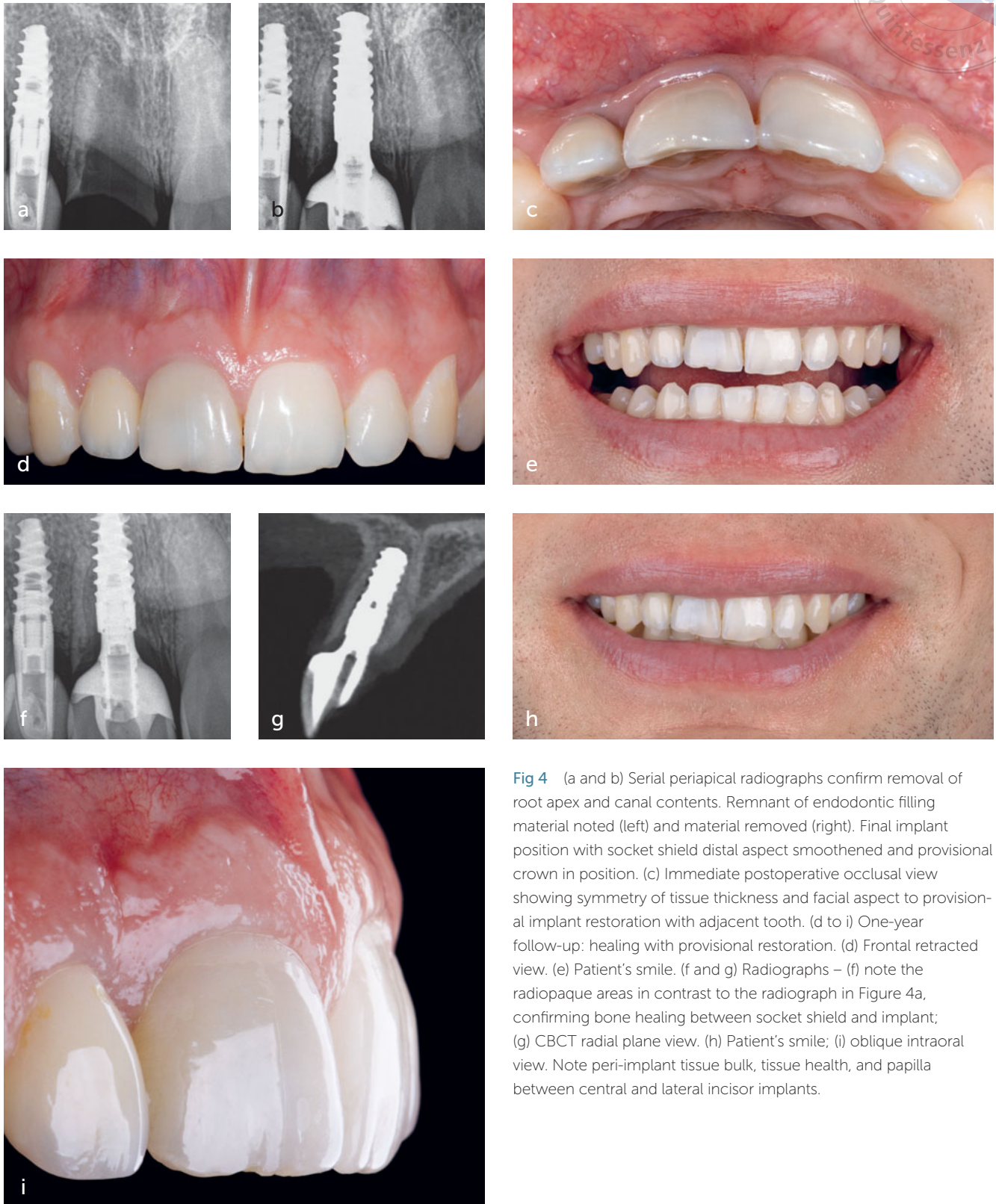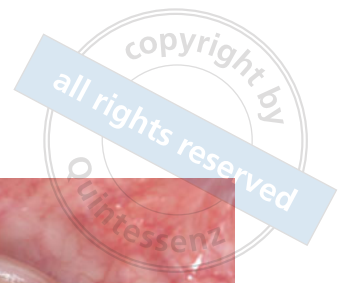and coworkers<sup>13</sup> reported that routinely grafting the socket gap might not be necessary. Gluckman and coworkers<sup>7,12</sup> motivated that exposure may be prevented by socket-shield height reduction to bone crest as well as by modifying from a bevel to a chamfer of the coronal socket-shield.<sup>7,12</sup> Nonetheless, while some questions may have been answered, it is clear that a high level of skill, experience, and training in implant dentistry are required for these procedures.

The socket-shield technique is no longer experimental after ten years of worldwide clinical application. Five-year volumetric data have confirmed the value of the technique in preventing facial ridge collapse in immediate implant placement.<sup>4</sup> Four-year results have reported the implant survival rate to be comparable to conventional immediate and early/delayed implant placement.<sup>7</sup> These studies also report in detail the possible complications and their likelihood of occurring. It has also long since been known that contrary to what was proposed by the original pioneers of the technique, it is not necessary to apply enamel matrix derivative to the inner dentin surface of the socket-shield.<sup>3,4</sup> It is also now known that preparing the socket-shield to above bone crest as per the original proof-of-principle technique,<sup>2</sup> as well as the very similar variation later reported by Siompas et al,<sup>8</sup> may lead to exposure of the root portion through the overlying soft tissue (for both these approaches). It is also known from both animal and human histology that bone can grow between the implant and the socket-shield.<sup>2,14</sup> Radiopaque change is routinely noted between the immediate postoperative and follow-up radiographs (Figs 4a, b, f, and g). There is also some data to report that grafting of the gap might not be necessary.<sup>13</sup> However, the current authors prefer stabilizing the blood clot with a gap graft in an attempt to preclude coronal soft tissue downgrowth. The current authors also de-

bate that drilling through the root in the original techniques was a significant challenge. The original 2010 publication stated that the osteotomy was drilled through the roots. The histological images clearly depicted implants positioned against the buccal bone plate, positioned far from the lingual bone plate. Thus, the above is our working group's interpretation of that data, in the absence of any other clear explanation stating otherwise, that the original protocol could not have been inclined lingually/palatally. The original osteotomies may have been prepared through the root while staying away from the beginning on the palatal side, but this description was absent from both the 2010 and 2017 publications, nor was it depicted in the diagrams or in the histological images. The root position does not always coincide with the planned implant position. The radial plane position of the maxillary anterior teeth also rarely coincides with a screw-retained prosthetic option. Moreover, drilling an osteotomy through tooth dentin may rapidly deteriorate expensive drills. Conventional extraction drills also typically have two or three cutting flutes that, among other things, create chatter, may be difficult to control, and might fracture the socket-shield. For these reasons, the careful preparation of the canal, determination and repeated verification of the root apex, and mesiodistal sectioning of the root with resection burs, is advocated in the partial extraction therapy protocol. Lastly, also as proposed by Gluckman et al,<sup>12</sup> an S-shaped prosthetic emergence profile is preferable (Fig 4f and g) to avoid exposure and to allow maximal soft tissue infill. This is a slight modification from a bevel to a preferable chamfer, with additional and even space between the socket-shield and implant/abutment.

When the knowledge gained over the past decade of experience is applied, the technique – if executed correctly and if





**Fig 4** (a and b) Serial periapical radiographs confirm removal of root apex and canal contents. Remnant of endodontic filling material noted (left) and material removed (right). Final implant position with socket shield distal aspect smoothed and provisional crown in position. (c) Immediate postoperative occlusal view showing symmetry of tissue thickness and facial aspect to provisional implant restoration with adjacent tooth. (d to i) One-year follow-up: healing with provisional restoration. (d) Frontal retracted view. (e) Patient's smile. (f and g) Radiographs – (f) note the radiopaque areas in contrast to the radiograph in Figure 4a, confirming bone healing between socket shield and implant; (g) CBCT radial plane view. (h) Patient's smile; (i) oblique intraoral view. Note peri-implant tissue bulk, tissue health, and papilla between central and lateral incisor implants.





local factors and favorable healing coincide – can achieve very positive outcomes, even in the most challenging of clinical scenarios such as the maxillary central and lateral incisors as adjacent implants (Figs 4c to i).

## Conclusions

Today, the socket-shield technique is undoubtedly an established procedure in the spectrum of implant dentistry. The procedure is technique sensitive and challenging, and should still be reserved for the knowledgeable, experienced, and skilled clin-

ician. However, a clear and concise protocol has previously been lacking. The technique needs to be safe and reproducible because even evidence-based treatment in the wrong hands may produce adverse results and obscure an accurate evaluation of its performance. Nevertheless, much has been learnt since 2010, and thus this step-by-step partial extraction therapy protocol outlines the most up-to-date guideline to carrying out the procedure in pursuit of a reproducible, reliable, and safe treatment in conjunction with immediate implant placement.

## References

1. Chen ST, Buser D. Clinical and esthetic outcomes of implants placed in postextraction sites. *Int J Oral Maxillofac Implants* 2009;24(suppl):186–217.
2. Hürzeler MB, Zuhr O, Schupbach P, Rebele SF, Emmanouilidis N, Fickl S. The socket-shield technique: A proof-of-principle report. *J Clin Periodontol* 2010;37:855–862.
3. Bäumer D, Zuhr O, Rebele S, Schneider D, Schupbach P, Hürzeler M. The socket-shield technique: first histological, clinical, and volumetric observations after separation of the buccal tooth segment – a pilot study. *Clin Implant Dent Relat Res* 2015;17:71–82.
4. Bäumer D, Zuhr O, Rebele S, Hürzeler M. Socket-shield Technique for immediate implant placement – clinical, radiographic and volumetric data after 5 years. *Clin Oral Implants Res* 2017;28:1450–1458.
5. Gluckman H, Salama M, Du Toit J. Partial extraction therapies (PET) part 1: maintaining alveolar ridge contour at pontic and immediate implant sites. *Int J Periodontics Restorative Dent* 2016;36:681–687.
6. Gluckman H, Salama M, Du Toit J. Partial extraction therapies (PET) part 2: procedures and technical aspects. *Int J Periodontics Restorative Dent* 2017;37:377–385.
7. Gluckman H, Salama M, Du Toit J. A retrospective evaluation of 128 socket-shield cases in the esthetic zone and posterior sites: partial extraction therapy with up to 4 years follow-up. *Clin Implant Dent Relat Res* 2018;20:122–129.
8. Siormpas KD, Mitsias ME, Kotsiotou-Siormpa E, Garber D, Kotsakis GA. Immediate implant placement in the esthetic zone utilizing the “root-membrane” technique: clinical results up to 5 years postloading. *Int J Oral Maxillofac Implants* 2014;29:1397–1405.
9. Gluckman H, Pontes CC, Du Toit J. Radial plane tooth position and bone wall dimensions in the anterior maxilla: a CBCT classification for immediate implant placement. *J Prosthet Dent* 2018;120:50–56.
10. Morton D, Galluci G, Lin WS, et al. Group 2 ITI Consensus Report: Prosthodontics and implant dentistry. *Clin Oral Implants Res* 2018;29(suppl 16):215–223.
11. Glocker M, Attin T, Schmidlin PR. Ridge preservation with modified “socket-shield” technique: a methodological case series. *Dent J* 2014;2:11–21.
12. Gluckman H, Nagy K, Du Toit J. Prosthetic management of implants placed with the socket-shield technique. *J Prosthet Dent* 2019;121:581–585.
13. Han CH, Park KB, Mangano FG. The modified socket-shield technique. *J Craniofac Surg* 2018;29:2247–2254.
14. Du Toit J, Gluckman H. Synthetic bone substitute materials. In: Miron RJ, Zhang Y (eds). *Next-Generation Biomaterials for Bone & Periodontal Regeneration*. Quintessence Publishing, 2019.
15. Schwimer C, Pette GA, Gluckman H, Salama M, Du Toit J. Human histologic evidence of new bone formation and osseointegration between root dentin (unplanned socket-shield) and dental implant: case report. *Int J Oral Maxillofac Implants* 2018;33:e19–e23.